

# demodex: principal, conspirator, or bystander in dry eye

milton m. hom  
eyemage@mminet.net

9:20

# demodex: principal, conspirator, or bystander in dry eye

milton m. hom  
eyemage@mminet.net

## disclosures

last 12 months

allergan/abbvie  
bausch health  
novartis  
sun pharma  
kala pharma  
tarsus pharma  
hovione scientia  
silk-tech

last 12 months

sydnexis  
topcon  
eyenovia bio  
laboratoires Thea  
aurinia pharma  
eyevance pharma  
surface pharma  
nevakar, inc.

last 12 months

visus therapeutics  
aperta biosciences  
astareal, inc.  
azura ophthalmics  
aldehyra therapeutics  
allysta  
vyluma  
nicox

## demodex

The basics

Diagnostic techniques

Rosacea

Treatments

## The basics

## Mites

Reports of Demodex mites were  
recorded as early as 1841

Demodex mites exist in every adult  
over 18 years old.

<https://www.rosacea.org/patients/the-ecology-of-your-face-demodex-rosacea-and-you>

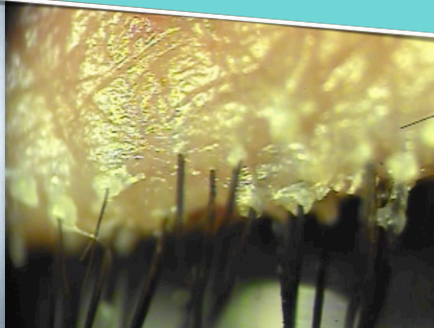
## Mites

Reports of Demodex mites were  
recorded as early as 1841

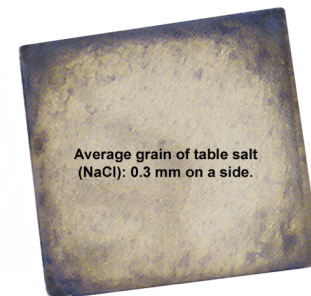
Demodex mites exist in every adult  
over 18 years old.

<https://www.rosacea.org/patients/the-ecology-of-your-face-demodex-rosacea-and-you>

## Cylindrical dandruff



Follicle Mite (*Demodex*)



Average grain of table salt  
(NaCl): 0.3 mm on a side.

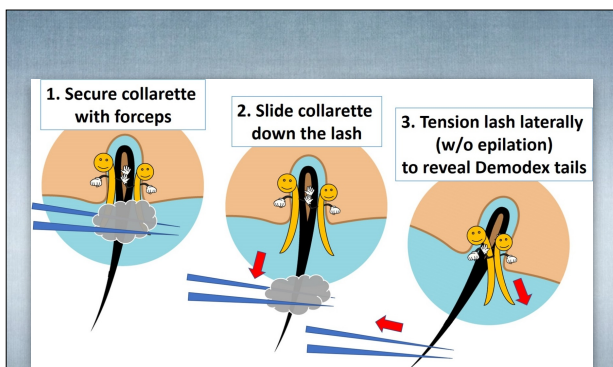
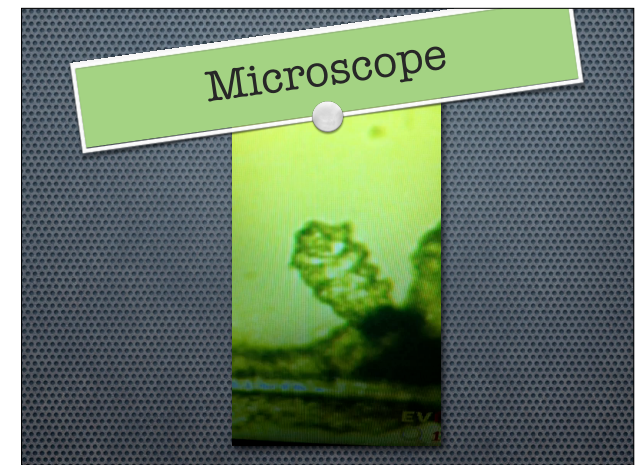
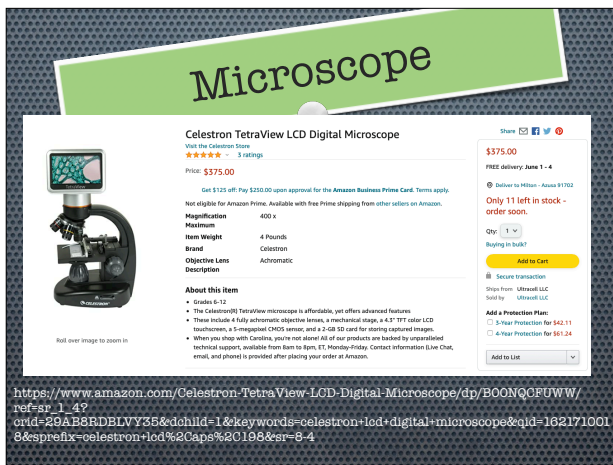
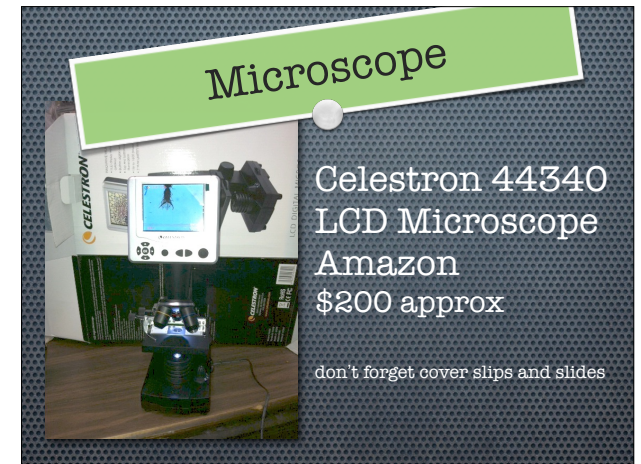A follicle mite (*Demodex brevis*) compared in size with an average grain of table salt (NaCl). The mite is about 1/2 the length of one side of the grain. Magnification 400x.

<http://waynesword.palomar.edu/redmite7a.htm>

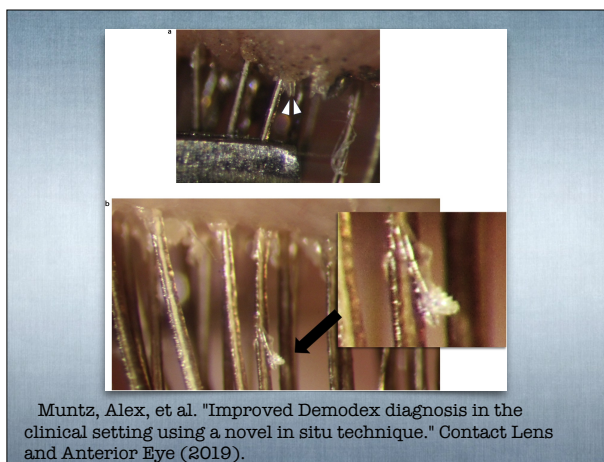




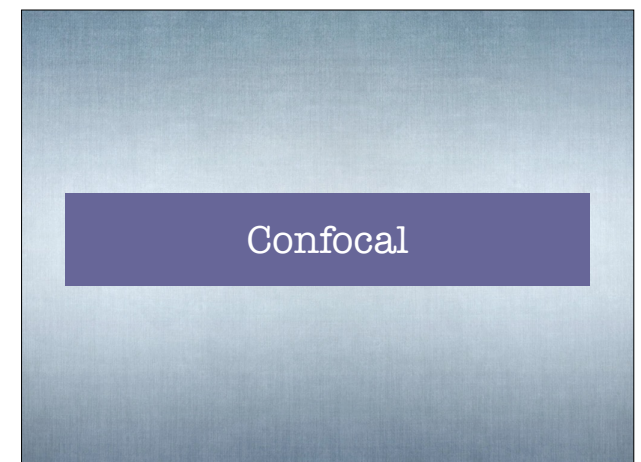## Epilate and microscope



Muntz, Alex, et al. "Improved Demodex diagnosis in the clinical setting using a novel in situ technique." Contact Lens and Anterior Eye (2019).



Muntz, Alex, et al. "Improved Demodex diagnosis in the clinical setting using a novel in situ technique." Contact Lens and Anterior Eye (2019).

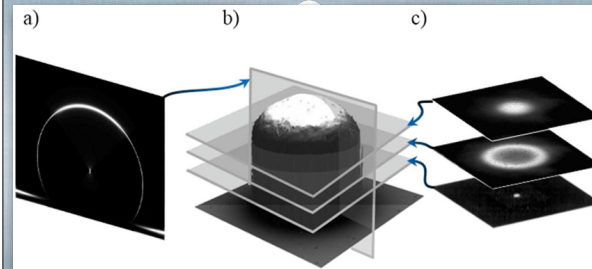




## Confocal

Non-invasive  
Real time  
Learning curve

Pondelis, Nicholas; Hom, Milton M.; O'Dell, Leslie E.; Jamali, Arslan; Hamrah, Pedram. Detection and Assessment of Treatment Efficacy of Demodex Blepharitis by In Vivo Confocal Microscopy. Invest Ophthalmol Vis Sci 2017;59(8):ARVO E-Abstract: 136 - B0050.

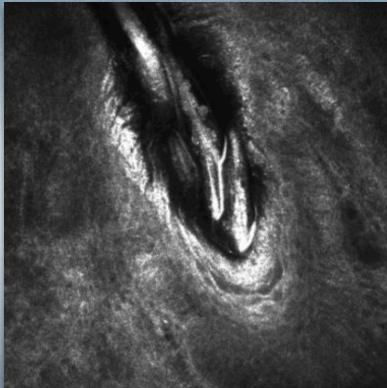


## Confocal

“Demodex brevis normally resides singly in the sebaceous and meibomian glands.”

De Venecia AB, Siong RL. Demodes sp. infestation in anterior blepharitis, meibomian gland dysfunction, and mixed blepharitis. Philipp J Ophthalmol 2011;36:15Y22.

Hom, Milton M., Katherine M. Mastrotta, and Scott E. Schachter. "Demodex." Optometry and Vision Science 90.7 (2013): e198-e205.



## Principal

## Facial ecology

Principal- cause?  
Relationship to dry eye, MGD and blepharitis

Hom, Milton M., Katherine M. Mastrotta, and Scott E. Schachter. "Demodex." Optometry and Vision Science 90.7 (2013): e198-e205.

## Dry eye

“significant relationship between lower Schirmer test score and higher OSDI rates and Demodex infestation”

Ayyildiz T, Sezgin FM. The Effect of Ocular Demodex Colonization on Schirmer test and OSDI Scores in Newly Diagnosed Dry Eye Patients. Eye Contact Lens. 2020 Jan;46 Suppl 1:S39-S41. doi: 10.1097/ICL.0000000000000640. PMID: 31395313.

## Blepharitis

Blepharitis with demodex  
62.9% Sumer et. al.  
88% Alejo et.al.  
97% De Venecia and Siong

Sumer Z, Arici MK, Topalkara A, Ozcelik S, Yildirim S. [Incidence of Demodex folliculorum in chronic blepharitis patients]. Cumhuriyet Univ Tıp Fak Dergisi 2000;22:69Y72.

Alejo RL, Valenton MJ, Abendano R. Demodex folliculorum infestation of the lids in Filipinos. Philipp J Ophthalmol 1972;4:110Y3.

De Venecia AB, Siong RL. Demodes sp. infestation in anterior blepharitis, meibomian gland dysfunction, and mixed blepharitis. Philipp J Ophthalmol 2011;36:15Y22.

## Demodex & CL

“Demodex...in 92.86% of patients with intolerance to contact lenses.”

Tarkowski, Witold, Joanna Moneta-Wielgoś, and Daniel Młocicki. "Demodex sp. as a potential cause of the abandonment of soft contact lenses by their existing users." BioMed research international 2015 (2015).

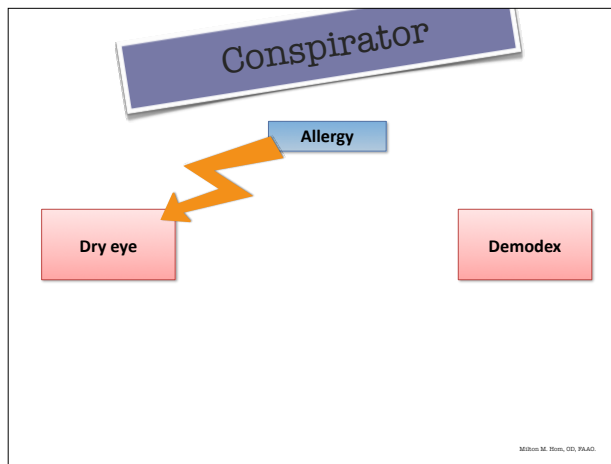
## demodex: principal, conspirator, or bystander in dry eye

1. Principal?
2. Dry eye and demodex symptoms are extremely alike
3. 74.7% ocular dryness
4. Chicken or egg?

Hom, Milton M., Katherine M. Mastrotta, and Scott E. Schachter. "Demodex." *Optometry and Vision Science* 90.7 (2013): e198-e205.

## Conspirator

## Demodex & allergy



### Rosacea

"up-regulation of Toll-like receptors 2.. [is seen] in the nasal mucosa of patients with symptomatic allergic rhinitis"

Fransson, Mattias, et al. "Up-regulation of Toll-like receptors 2, 3 and 4 in allergic rhinitis." *Respiratory research* 6.1 (2005): 100.

### Rosacea

"[Demodex] have been shown to activate the enzyme toll-like receptor-2 (TLR-2) signaling"

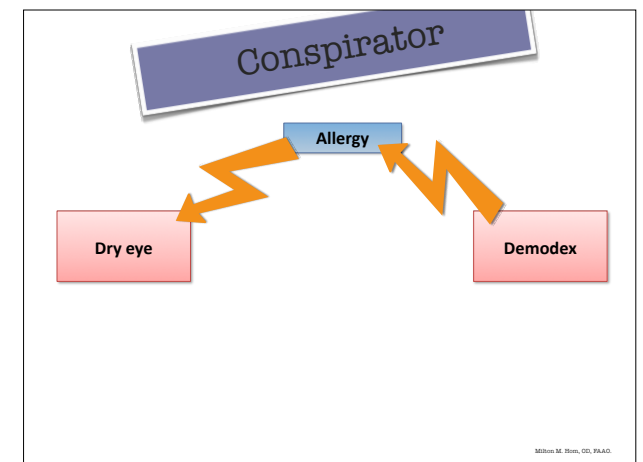
<https://www.rosacea.org/rosacea-review/2015/summer/new-studies-discuss-significance-of-demodex-in-rosacea-care>

Demodex → Toll like 2 receptor  
→ Rhinitis

### Allergy

"Demodex should be investigated in patients with AR [allergic rhinitis]"

Cengiz, A. R. L. İ., et al. "The Incidence of Demodex folliculorum in the Combination of Allergic Rhinitis and Diabetes Mellitus." *Iranian journal of parasitology* 14.3 (2019): 459.  
Yengil E, Cevik C, Kaya OA, Taner M, Akkoca AN, Ozer C. Relationship between Demodex folliculorum and allergic rhinitis in adults. *Acta Med Mediterr.* 2014; 30:27-31





## Demodex & asthma



[https://www.youtube.com/watch?v=IQH\\_4Le43EY](https://www.youtube.com/watch?v=IQH_4Le43EY)

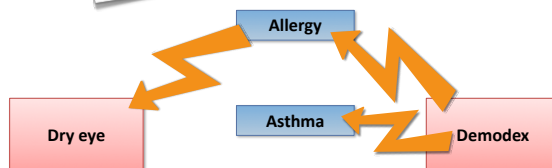
1:13

## Dermatologic

Case report  
2 Asthmatic cats  
Treated with inhalers  
Demodex cati present

Bizikova P. Localized demodicosis due to Demodex cati on the muzzle of two cats treated with inhalant glucocorticoids. Vet Dermatol. 2014 Jun;25(3):222-e58. doi: 10.1111/vde.12123. Epub 2014 Apr 11. PMID: 24720463.

## Conspirator



William M. Stein, MD, FRCO

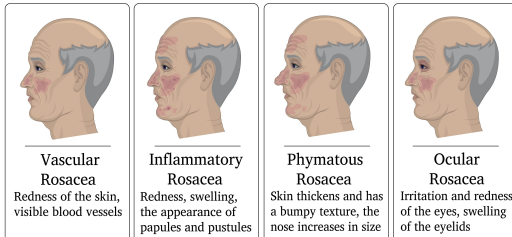
## Demodex & rosacea

## Rosacea

16 million Americans  
415 million worldwide  
95% unaware prior to their diagnosis  
90% condition had lowered their self-confidence  
41% avoid public contact or cancel social engagements  
51% said they had even missed work

<https://www.rosacea.org>

## Rosacea



<https://charlestondermatology.com/blog/dealing-with-rosacea/>

## Rosacea

Rosacea and demodex  
Meta-analysis of 48 studies  
10 different countries  
28,527 subjects  
Rosacea patients 7-8x chance have Demodex

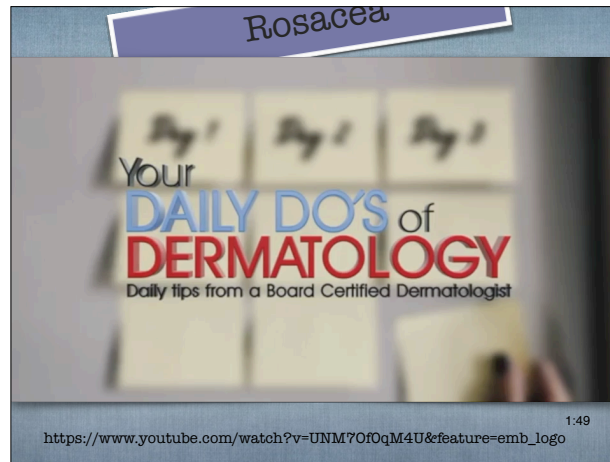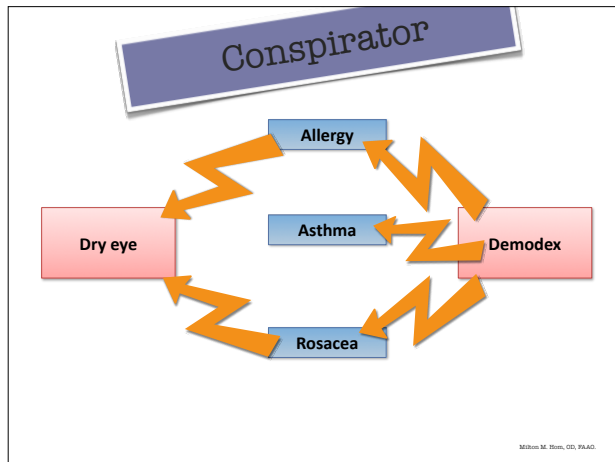
Zhao YE, Wu LP, Peng Y, Cheng H. Retrospective analysis of the association between Demodex infestation and rosacea. Arch Dermatol 2010;146:896Y902.

## Rosacea

“Demodex mites...found in more than four times greater numbers on the facial skin of rosacea sufferers”

<https://www.rosacea.org/rosacea-review/2015/summer/new-studies-discuss-significance-of-demodex-in-rosacea-care>





**Rosacea**

Common Triggers

|                  |     |
|------------------|-----|
| Sun exposure     | 81% |
| Emotional stress | 79% |
| Hot weather      | 75% |
| Wind             | 57% |
| Heavy exercise   | 56% |
| Alcohol          | 52% |
| Hot baths        | 51% |
| Cold weather     | 46% |
| Spicy foods      | 45% |
| Humidity         | 44% |
| Indoor heat      | 41% |

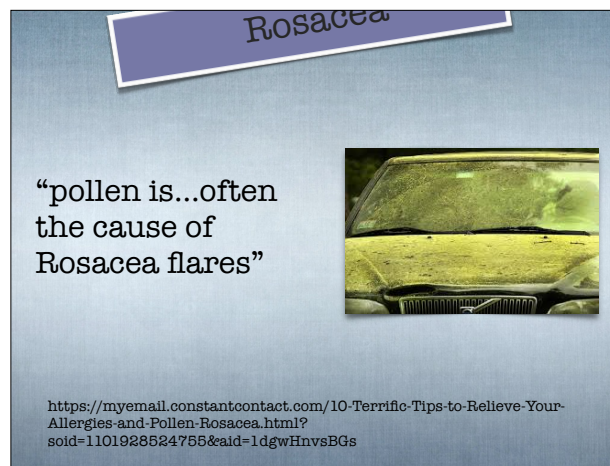
<https://www.rosacea.org>

**Rosacea**

Common Triggers

|                  |     |
|------------------|-----|
| Sun exposure     | 81% |
| Emotional stress | 79% |
| Hot weather      | 75% |
| Wind             | 57% |
| Heavy exercise   | 56% |
| Alcohol          | 52% |
| Hot baths        | 51% |
| Cold weather     | 46% |
| Spicy foods      | 45% |
| Humidity         | 44% |
| Indoor heat      | 41% |

<https://www.rosacea.org>



| Weather     | Asthma              | Dry eye | Allergic conjunctivitis | Rosacea             |
|-------------|---------------------|---------|-------------------------|---------------------|
| Temperature | High (or very cold) | High    | High                    | High (or very cold) |
| Pollen      | High                | High    | High                    | High                |
| Humidity    | High (or very dry)  | Low     | High (dust mites)       | High (or very dry)  |

Harthan JS, Hom MM, O'Dell L, Halleran OC. Humidity Levels and Temperature Effects on Dry Eye Symptom Scores. Optom Vis Sci American Academy of Optometry 2017 Chicago IL  
Halleran OC, Hippolito K, Harthan J, Hom MM. The role of Pollen counts on the Signs and Symptoms of Ocular Surface disease. Optom Vis Sci American Academy of Optometry 2017 Chicago IL  
Hedhly, A., J. I. Hormaza, and M. Herrero. "The effect of temperature on pollen germination, pollen tube growth, and stigmatic receptivity in peach." Plant Biology 7:05 (2005): 476-483.

| Weather     | Asthma              | Dry eye | Allergic conjunctivitis | Rosacea             | Demodex |
|-------------|---------------------|---------|-------------------------|---------------------|---------|
| Temperature | High (or very cold) | High    | High                    | High (or very cold) | High    |
| Pollen      | High                | High    | High                    | High                | High    |
| Humidity    | High (or very dry)  | Low     | High (dust mites)       | High (or very dry)  | High    |

Harthan JS, Hom MM, O'Dell L, Halleran OC. Humidity Levels and Temperature Effects on Dry Eye Symptom Scores. Optom Vis Sci American Academy of Optometry 2017 Chicago IL  
Halleran OC, Hippolito K, Harthan J, Hom MM. The role of Pollen counts on the Signs and Symptoms of Ocular Surface disease. Optom Vis Sci American Academy of Optometry 2017 Chicago IL  
Hedhly, A., J. I. Hormaza, and M. Herrero. "The effect of temperature on pollen germination, pollen tube growth, and stigmatic receptivity in peach." Plant Biology 7:05 (2005): 476-483.

demodex: principal, conspirator, or bystander in dry eye

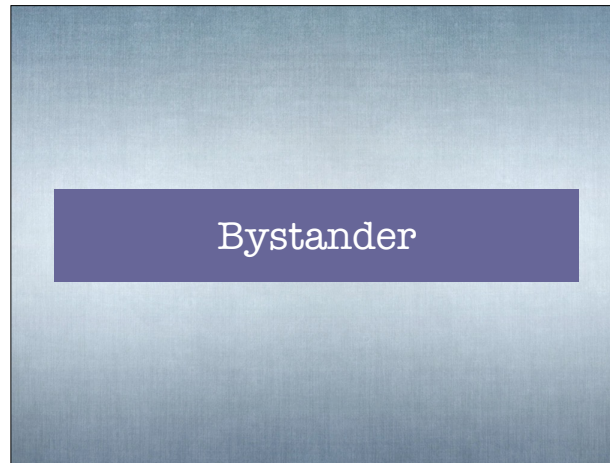
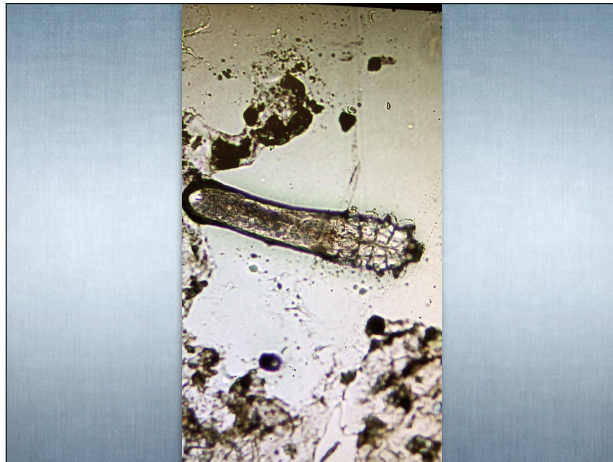1. Rosacea, dry eye, allergy and asthma all have the same triggers
2. Demodex = conspirator? (cats)

8:55

**Dermatologic**

Packing tape  
Place on cheeks  
Microscope





**Commensal**

“mites are an often neglected member of the human skin microbiome. Mostly they are commensals”

Glanner-Engelshofen BM, Ruzicka T, Reinholz M. Efficient isolation and observation of the most complex human commensal, *Demodex* spp. *Exp Appl Acarol.* 2018 Sep;76(1):71-80. doi: 10.1007/s10493-018-0289-0. Epub 2018 Sep 6. PMID: 30191497.

**Commensal**

“Demodex can live in the skin either as a harmless commensal organism or as a pathogenic agent.”

Foley R, Kelly P, Gatault S, Powell F. Demodex: a skin resident in man and his best friend. *J Eur Acad Dermatol Venereol.* 2021 Jan;35(1):62-72. doi: 10.1111/jdv.16461. Epub 2020 May 15. PMID: 32294279.

**Commensal**

“Demodex mites normally have a symbiotic relationship with humans...It is possible in this role that they may even confer a mutualistic host benefit”

Lacey N, Ni Raghallaigh S, Powell FC. Demodex mites--commensals, parasites or mutualistic organisms? *Dermatology.* 2011;222(2):128-30. doi: 10.1159/000323009. Epub 2011 Jan 11. PMID: 21228556.

**Commensal**

“If mite numbers increase to a critical level...they possibly develop a pathogenic role causing host ‘insult’.”

Lacey N, Ni Raghallaigh S, Powell FC. Demodex mites--commensals, parasites or mutualistic organisms? *Dermatology.* 2011;222(2):128-30. doi: 10.1159/000323009. Epub 2011 Jan 11. PMID: 21228556.

**Facial ecology**

Demodex mites are a natural part of this human microbiome

Demodex may be part of a natural cleaning system. Consumes excess oil

Mutualistic relationship: Helps occupant, Helps host  
Serve a useful function by feeding off of dead skin cells to help rid the face of waste

<https://www.rosacea.org/patients/the-ecology-of-your-face-demodex-rosacea-and-you>

demodex: principal, conspirator, or bystander in dry eye

1. Bystander?
2. Demodex mites exist in every adult over 18 years old.
3. Sub-clinical vs Clinically apparent
4. Commensal vs Parasitic



## Commensal

"Demodex...likely reflects an imbalance in the external ocular ecology...Treatment should not be aimed at total eradication of the mite but rather restoring the ocular ecology to a balanced state."

Nicholls SG, Oakley CL, Tan A, Vote BJ. Demodex species in human ocular disease: new clinicopathological aspects. *Int Ophthalmol*. 2017 Feb;37(1):303-312. doi: 10.1007/s10792-016-0249-9. Epub 2016 May 9. PMID: 27160273.

## Treatments

## Tea Tree Oil

Tea Tree oil  
Ocusoft Oust  
Cliradex  
Blephadex  
Lunovus

### Blephadex™ Eyelid Wipes and Foam (At-Home Use)

- Made with a patented blend of Tea Tree Oil, Coconut Oil and a gentle lid cleanser
- Designed to treat both blepharitis and Demodex
- Less expensive than other brands!
- Comfortable with no stinging, burning or bad smell
- Only \$10 to practice and \$19.95 to patient

**Blephadex™**  
Science Based Lid Care



MACULAR  
HEALTH™

## Blephadex

Blephadex eyelid wipes one eye  
No treatment other eye  
6 M 14 F  
median age: 63.5

Wong, Katherine, et al. "The effect of Blephadex™ Eyelid Wipes on Demodex mites, ocular microbiota, bacterial lipase and comfort: a pilot study." *Contact Lens and Anterior Eye* 42.6 (2019): 652-657.

## Blephadex

"Although a statistically significant reduction in Demodex count was observed in treated eyes, overall numbers of Demodex were low."

Wong, Katherine, et al. "The effect of Blephadex™ Eyelid Wipes on Demodex mites, ocular microbiota, bacterial lipase and comfort: a pilot study." *Contact Lens and Anterior Eye* 42.6 (2019): 652-657.

## Lid hygiene

Avenova (NovaBay) hypochlorous acid  
vs.  
Cliradex (BioTissue) TTO  
vs.  
mineral oil

Kabat, Alan G. "In-Vitro Demodicidal Activity of Commercial Lid Hygiene Products." *Investigative Ophthalmology & Visual Science* 59.9 (2018): 905-905.

## Lid hygiene

Avenova: 88 minutes  
Cliradex: 40 minutes  
mineral oil: 90 minutes

Kabat, Alan G. "In-Vitro Demodicidal Activity of Commercial Lid Hygiene Products." *Investigative Ophthalmology & Visual Science* 59.9 (2018): 905-905.

## Lid hygiene

"Avenova was no more effective against Demodex mites in-vitro than 100% mineral oil, which is known to be innocuous."  
—Al Kabat

Kabat, Alan G. "In-Vitro Demodicidal Activity of Commercial Lid Hygiene Products." *Investigative Ophthalmology & Visual Science* 59.9 (2018): 905-905.



## IPL

"in vitro real-time effects of intense pulsed light (IPL) on a Demodex mite."

"administration of five IPL pulses, the temperature of the slide increased from room temperature to 49°C. [120 F]"

"Immediately afterward, the Demodex mite became completely immobilized."

Fishman, Harvey A., Laura M. Periman, and Ami A. Shah. "Real-Time Video Microscopy of In Vitro Demodex Death by Intense Pulsed Light." Photobiomodulation, Photomedicine, and Laser Surgery (2020). APA

<https://www.youtube.com/watch?v=OLEjlp3txGQ>

## Manuka Honey

<https://www.youtube.com/watch?v=RthnYyVnTrw>

## Manuka Honey

"Manuka honey was comparable with 50% tea tree oil, an established treatment for ocular Demodex."

Frame, Katie, et al. "Comparing the in vitro effects of MGO™ Manuka honey and tea tree oil on ocular Demodex viability." Contact Lens and Anterior Eye 41.6 (2018): 527-530.

## Manuka Honey Ingredients



[https://www.youtube.com/watch?v=\\_LfD39Cmu8g](https://www.youtube.com/watch?v=_LfD39Cmu8g)

## Hom's banned list

1. Steroids
2. Prostaglandins

## Steroids

82 female patients with perioral dermatitis  
70 control female subjects.

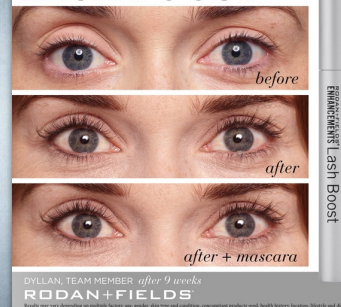Mite density increased significantly with length of treatment with topical steroids ( $p < 0.001$ )

Dolenc-Voljc M, Pohar M, Lunder T. Density of Demodex folliculorum in perioral dermatitis. Acta Derm Venereol. 2005;85(3):211-5.

## Lash serums

### LASH BOOST

"Isopropyl cloprostenate is a synthetic type of compound known as a prostaglandin analog"



<https://www.buzzfeednews.com/article/stephaniemcneal/rodan-and-fields-lash-boost>

## Lash serums

Anti-cancer drugs decrease Epidermal Growth Factor (EGF)  
EGF inhibits demodex  
Decreasing EGF results in more demodex  
Prostaglandins (PGAs) also decrease EGF  
Clinically sees higher mite counts with glaucoma patients on PGAs (Nick Optiz, OD)

Lacey, Mervin, Siona N. Baghalligh, and Frank C. Powell. "Demodex mites-commensals, parasites or mutualistic organisms." Dermatology 222.2 (2011): 128-130.  
Gerben, Peter A., et al. "Density of Demodex folliculorum in patients receiving epidermal growth factor receptor inhibitors." Dermatology 225.5 (2011): 144-147.  
Wang, Dingzhi, and Raymond N. Dubois. "Prostaglandins and cancer" Gut 55.1 (2006): 115-122.  
Serrero, Giselle, and Nancy M. Lepak. "Prostaglandin F2a Inhibits Epidermal Growth Factor Binding to Cellular Receptors on Adipocyte Precursors in Primary Culture." Biochemical and biophysical research communications 212.3 (1995): 1125-1132.



## Drugs

## Demodex

### Demodex Blepharitis

## Blepharitis

#### Selected Clinical trials

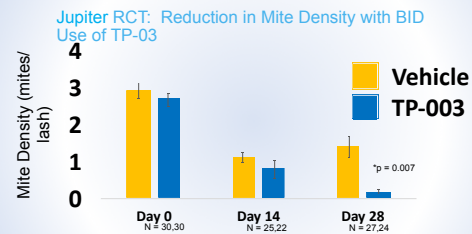
|                          | Form    | Dosing   | Proposed Indication           |
|--------------------------|---------|----------|-------------------------------|
| Tarsus (saroliner)       | Drop    | BID      | Demodex                       |
| Aperta (Spinosod)        | ung     | N/A      | Blepharitis<br>Demodex        |
| Azura (selenium sulfide) | ung     | 2 x week | Blepharitis<br>MGD/CL dryness |
| Hovione (minocycline)    | ung     | BID      | MGD                           |
| (Ivermectin)             | Topical | Weekly?  | Demodex                       |



“monthly oral parasiticide product for dogs.”



McTier, Tom L., et al. "Discovery of sarolaner: a novel, orally administered, broad-spectrum, isoxazoline ectoparasiticide for dogs." *Veterinary parasitology* 222 (2016): 3-11.




#### Selected Clinical trials

|                          | Form    | Dosing   | Proposed Indication           |
|--------------------------|---------|----------|-------------------------------|
| Tarsus (saroliner)       | Drop    | BID      | Demodex                       |
| Aperta (Spinosod)        | ung     | N/A      | Blepharitis<br>Demodex        |
| Azura (selenium sulfide) | ung     | 2 x week | Blepharitis<br>MGD/CL dryness |
| Hovione (minocycline)    | ung     | BID      | MGD                           |
| (Ivermectin)             | Topical | Weekly?  | Demodex                       |

## Spinosad

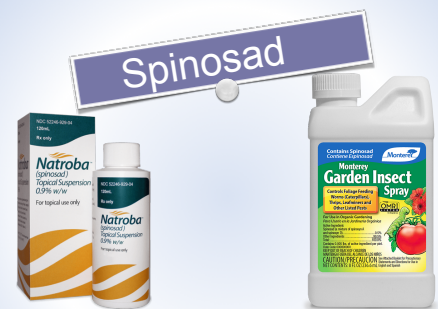“Spinosad is...made by a soil bacterium that can be toxic to insects. It is used to control a wide variety of pests...thrips, leafminers, spider mites, mosquitoes, ants, fruit flies and others.”

<https://www.apertabio.com>



<https://www.youtube.com/watch?v=7866pqzY0Y>

1:36

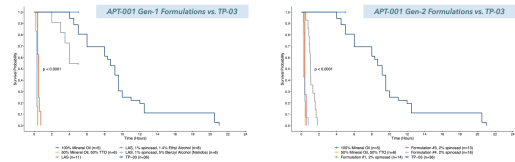


Head lice

Bug spray



# APT-001: Potent & Superior Demodex Killing Across Multiple Formulations API, Format, and Formulation Expected to Yield Best-In-Class Product





## Ivermectin

"1 dose of oral ivermectin (200 µg/kg).  
Repeat the treatment after 7 days"

Holzchuh FG, Hida RY, Moscovici BK, Villa Albers MB, Santo RM, Kara-José N, Holzchuh R. Clinical treatment of ocular Demodex folliculorum by systemic ivermectin. Am J Ophthalmol. 2011 Jun;151(6):1030-1034.e1. doi: 10.1016/j.ajo.2010.11.024. Epub 2011 Feb 19. PMID: 21334593.

## Ivermectin

"Statistical improvement was observed  
in the absolute number of D.  
folliculorum...Schirmer I...and tear film  
break-up time improved statistically"

Holzchuh FG, Hida RY, Moscovici BK, Villa Albers MB, Santo RM, Kara-José N, Holzchuh R. Clinical treatment of ocular Demodex folliculorum by systemic ivermectin. Am J Ophthalmol. 2011 Jun;151(6):1030-1034.e1. doi: 10.1016/j.ajo.2010.11.024. Epub 2011 Feb 19. PMID: 21334593.

## Ivermectin

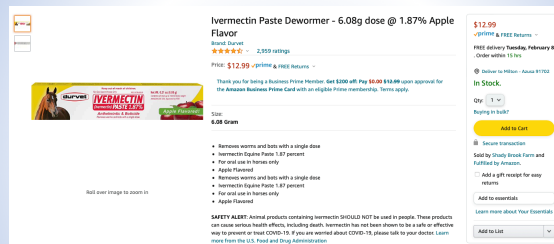
"topical ivermectin 1% cream on the  
eyelashes for 15 minutes once  
weekly...eyelid hygiene was  
performed once daily."

Choi Y, Eom Y, Gyn Yoon E. Efficacy of topical ivermectin 1% in the treatment of Demodex blepharitis. Cornea. 2021; 00:1-8.

## Ivermectin

"significantly improved symptoms,  
ocular surface staining, eyelid debris,  
redness/swelling, and telangiectasia as  
compared with eyelid hygiene alone."

Choi Y, Eom Y, Gyn Yoon E. Efficacy of topical ivermectin 1% in the treatment of Demodex blepharitis. Cornea. 2021; 00:1-8.



[https://www.amazon.com/Ivermectin-Paste-Dewormer-6-08g-Flavor/dp/B000HHLWPI/ref=sr\\_1\\_11?crd=11017LTRIOD0S&keywords=ivermectin&qid=1643993892&srefix=ivermectin%2Caps%2C165&sr=8-11](https://www.amazon.com/Ivermectin-Paste-Dewormer-6-08g-Flavor/dp/B000HHLWPI/ref=sr_1_11?crd=11017LTRIOD0S&keywords=ivermectin&qid=1643993892&srefix=ivermectin%2Caps%2C165&sr=8-11)



<https://www.youtube.com/watch?v=34KFHLbWWIE>

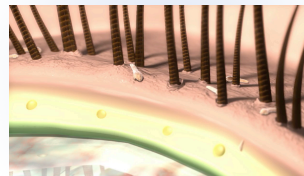
1:06



2:21

<https://www.youtube.com/watch?v=wB3Uff6jUY&t=183s>

## Demodex Infestation



1:07

Thank you!

Milton M. Hom, OD, FAAO, FACAAl(Sc).  
[eyemage@mminternet.com](mailto:eyemage@mminternet.com)